

Development and Evaluation of a Remote Patient Monitoring System in Autologous Breast Reconstruction

Stefan L.M. Hummelink, PhD*
 Vera A.A. Paulus, MD*
 Eva C. Wentink, PhD†
 Dietmar J.O. Ulrich, MD, PhD*

Background: Flap monitoring after a deep inferior epigastric perforator flap breast reconstruction is crucial to detect complications in time. A novel and innovative wireless device has been developed and tested in a feasibility study. This study describes our experience with remote patient monitoring via this device in postoperative monitoring of deep inferior epigastric perforator flaps.

Methods: Following a deep inferior epigastric perforator breast reconstruction, the “Free Flap Patch” was adhered to the flap, continuously measuring temperature and tissue saturation. Data were stored locally on the patch and analyzed in a retrospective manner. Raw analog-digital-conversion values from the red- and infrared sensors, delta muscle saturation (dSmO₂), and estimated tissue oxygenation (StO₂) were assessed and compared with clinical records.

Results: No adverse events related to the device were recorded. One patient suffered flap loss; a decrease in estimated tissue oxygenation was measured with the device in situ. No deviations in clinical variables were recorded in the uncompromised flaps.

Conclusions: A wearable patient monitoring device was successfully utilized in clinical practice. In one patient, a flap failure was recorded where the PPG-derived StO₂ parameter was indicative for this event. The Free Flap Patch has the potential of automatically predicting blood supply issues in an early stage. More data are needed for clinical validation. (*Plast Reconstr Surg Glob Open* 2022;10:e4008; doi: 10.1097/GOX.0000000000004008; Published online 5 January 2022.)

INTRODUCTION

Microsurgical free flap transfer is the backbone of reconstructive surgery. The first 72 hours after microsurgical flap transfer are, however, critical for procedure success.^{1,2} When vascular complications occur, 70%–80% of the cases can be successfully revised with timely intervention. Shortening the time interval between the onset of ischemia, and its clinical recognition, is imperative for flap survival.^{3–6}

The process of monitoring these free flaps is, however, time-consuming, subjective, and obtrusive for both the patient and the healthcare professional.^{7,8} It would be ideal if technology could take up this crucial

task. Therefore, we set out to develop a miniature monitoring system, the so-called Free Flap Patch, capable of comparing vital parameters of a free flap to reference healthy skin in a nonobtrusive and noninvasive manner.

This article describes the first steps of the development of a smart patch for continuous remote postoperative patient monitoring in deep inferior epigastric artery perforator (DIEP) flap breast reconstructions. We share our results of this feasibility study, evaluating whether it can be worn safely during hospital admission, its ability to capture clinically relevant variables in free flaps, and which recorded parameters are indicative for flap loss.

MATERIALS AND METHODS

Patients who were scheduled for a uni- or bilateral DIEP flap breast reconstruction were recruited in the period between October 2019 and November 2020.

The DIEP flaps were monitored per default hospital protocol by the nursing staff. For the first 48 hours, flaps are monitored hourly, to be reduced to 4-hour checkups until discharge. Nursing staff assesses the flap for audible

From the *Department of Plastic Surgery, Radboudumc, Nijmegen, the Netherlands; and †imec@Holst Netherlands, Eindhoven, the Netherlands.

Received for publication August 10, 2021; accepted October 28, 2021.

Copyright © 2022 The Authors. Published by Wolters Kluwer Health, Inc. on behalf of The American Society of Plastic Surgeons. This is an open-access article distributed under the terms of the [Creative Commons Attribution-Non Commercial-No Derivatives License 4.0 \(CCBY-NC-ND\)](https://creativecommons.org/licenses/by-nc-nd/4.0/), where it is permissible to download and share the work provided it is properly cited. The work cannot be changed in any way or used commercially without permission from the journal.

DOI: 10.1097/GOX.0000000000004008

Disclosure: The authors have no financial interest to declare in relation to the content of this article. No funding was received for this article.

Doppler pulsations (Dopplex SD2, Huntleigh Healthcare Ltd, Cardiff, Wales, UK), skin color, flap turgor, and temperature. These measurements were entered into electronic health record in conjunction with the exact timestamps these were performed. Ethical approval was obtained from the local ethical committee and recorded under number 2019-5472.

Preparation, Application, and Removal of Patch

imec@Holst (Eindhoven, the Netherlands) supplied the research-only Free Flap Patch (FFP) devices based on imec's Nightingale V2 wearable platform.⁹ The FFP consists of a reusable and disposable component. The reusable main section holds a rechargeable battery and imec's MUSEIC V2 chipset: a state-of-the-art low power bioprocessor chip.¹⁰ The disposable sensor part has two identical encapsulated probes targeted at the flap area and a reference healthy skin area. Each of the probes contains a custom-made reflective optical sensor (similar to a pulse oximeter) and temperature sensor. All materials in contact with the patient are biocompatible.

The data capture sequence is automatically initiated once both components are joined together. The entire unit is heat-sealed into a watertight pouch. The probes have an adhesive layer for convenient application to the patient. One probe serves as a reference and is placed on the sternum, measuring baseline parameters, and the probe with a longer lead is applied on a centered location of the free flap (Fig. 1). During application, care was taken not to obstruct the Doppler monitor location, as regular clinical flap monitoring care was not to be interfered with in this feasibility study.

The FFP was removed once the patient was discharged from the hospital, when a take-back occurred, or if the patient requested removal of the device. After removal of the patch, the skin was assessed for irritation, and patients were asked semistructured questions about their experience with the Free Flap Patch.

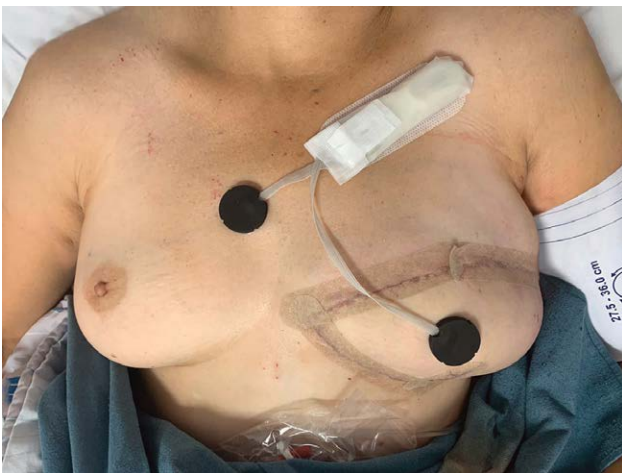

Fig. 1. FFP applied to unilateral DIEP flap, directly postoperative. Main module is placed caudal of the clavicle, and sensors are adhered to the DIEP flap and sternum (reference location).

Takeaways

Question: We set out develop a wearable for continuous remote postoperative patient monitoring in deep inferior epigastric artery perforator flap breast reconstructions. In this article, we describe our initial findings.

Findings: A total of 17 free flaps were successfully recorded, of which one flap required revision surgery. Of all variables assessed, estimated StO_2 was the best predictor for detecting this flap failure when compared with the reference location; temperature showed inconclusive trends.

Meaning: The Free Flap Patch device has the potential to predict blood supply issues in an early stage.

Data Analysis

Data were stored locally on the patch and analyzed in a retrospective manner by IMEC in MATLAB R2018a (The MathWorks Inc., Natick, Mass.). Temperature was derived from the raw thermistor data. Tissue saturation (StO_2) is estimated from the direct current through the (infra)red sensors within the probes following the principles of photoplethysmography (PPG), subsequently calculated with intervals of 90 seconds for stable measurements. For evaluation purposes, parameters such as analog-digital-conversion (ADC)-values from the red- and infrared sensors were also assessed, of which delta muscle saturation ($dSmO_2$) could be calculated.¹¹⁻¹⁴

Clinical data during the patient's admission, consisting of flap monitoring parameters, adverse events, and skin irritation, were retrieved from the electronic health records and pseudo-anonymously captured in CastorEDC (Castor, Amsterdam, the Netherlands).

RESULTS

In total, 18 patients ($n = 14$ unilateral, $n = 4$ bilateral) were recruited to participate in this feasibility study, which yielded a total of 22 ($n = 10$ left, $n = 12$ right) DIEP flaps eligible for application of the Free Flap Patch. The location for the main device, caudal of clavicle, was comfortable and did not hamper patients in their postoperative mobility and recovery. No requests were made to have the device removed. Little to no skin irritation was witnessed.

Five of the 22 worn patches experienced technical difficulties during data recording (automatic data capture incorrectly initiated, corrected via firmware update), of which no temperature and saturation data could be retrieved. In the remainder of the data ($n = 17$ flaps), one flap loss was recorded. Based on the clinical record, directly postoperatively, no Doppler location could be identified, but temperature, turgor, and capillary refill were normal. During hourly monitoring, the capillary refill became delayed, pin-prick test yielded little blood, and the skin color became paler (Fig. 2). Revision surgery commenced and the FFP was removed.

Of all variables assessed, estimated StO_2 was the best predictor for detecting this flap failure when compared with the reference location; temperature showed inconclusive trends (Fig. 3). When these data are plotted

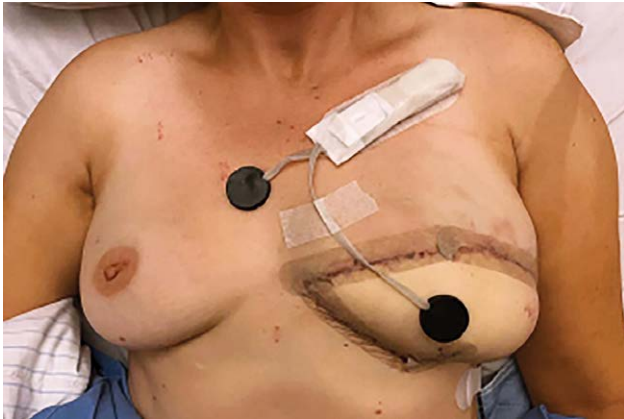

Fig. 2. DIEP flap with FFP applied; before revision surgery.

against the uneventful DIEPs, a downward trend outside the SD is visible (Fig. 4).

DISCUSSION

This is the first feasibility study investigating a wearable device designed to wirelessly monitor postoperative microvascular tissue transfer, to our knowledge. In our experiment, all patients, nurses, and plastic surgeons showed high adoptability of wearable patient monitoring device for DIEP flap breast reconstructions. Real-time data transmission from the Free Flap Patch to a smartphone had to be disabled during this exploratory pilot phase, as false-positives could negatively influence patient safety.

Retrospectively, considering the deviating trend of the failed flap, one could hypothesize that the decision on

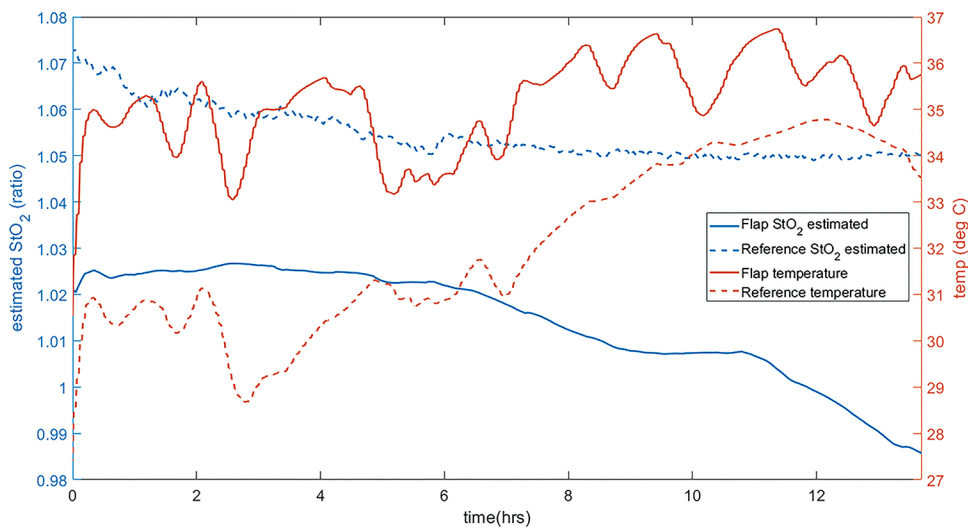


Fig. 3. Tissue oxygenation (StO_2) and temperature ($^{\circ}C$) of the failed DIEP flap before revision surgery.

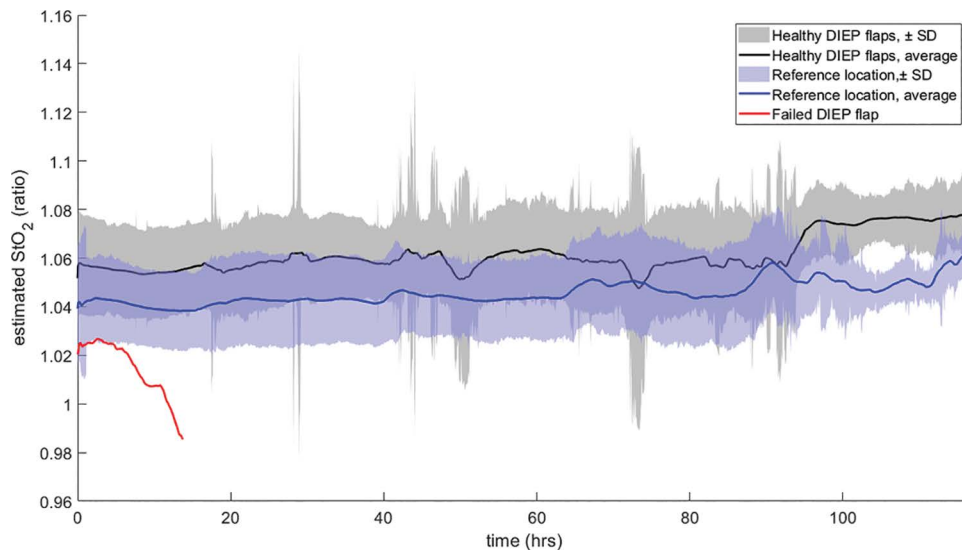


Fig. 4. Average direct current ratio and standard deviation (SD) of PPG (photoplethysmography) for reference and flap, variables used for StO_2 calculations. The red line represents the failed DIEP flap, well below the SD of the healthy flaps.

revision surgery could have taken place earlier, indicating the predictive potential of this innovation. However, more data are needed to validate the technology, and are fundamental for predictive algorithms. Afterward, the effect of real-time smartphone notifications on clinical decision-making and patient outcome will be investigated.

CONCLUSIONS

One flap failure was recorded, in which estimated tissue oxygenation (StO_2) seemed to describe the deteriorating status of the tissue most accurately. No skin irritation was found, and none of the patients were inconvenienced by wearing the device. The device has the potential to automatically predict blood supply issues in an early stage. Future studies will focus on gathering more clinical data and the clinical interpretation of these measurements.

Stefan L.M. Hummelink, PhD

Department of Plastic Surgery
Radboud University Medical Center
P.O. Box 9101
6500 HB Nijmegen
The Netherlands

E-mail: stefan.hummelink@radboudumc.nl

REFERENCES

1. Largo RD, Selber JC, Garvey PB, et al. Outcome analysis of free flap salvage in outpatients presenting with microvascular compromise. *Plast Reconstr Surg*. 2018;141:20e–27e.
2. Hummelink S. Post-operative monitoring of free flaps using a low-cost thermal camera: a pilot study. *Eur J Plast Surg*. 2020;43:589–596.
3. Wax MK. The role of the implantable Doppler probe in free flap surgery. *Laryngoscope*. 2014;124 (Suppl 1):S1–S12.
4. Carney MJ, Weissler JM, Tecce MG, et al. 5000 free flaps and counting: A 10-year review of a single academic institution's microsurgical development and outcomes. *Plast Reconstr Surg*. 2018;141:855–863.
5. Disa JJ, Cordeiro PG, Hidalgo DA. Efficacy of conventional monitoring techniques in free tissue transfer: an 11-year experience in 750 consecutive cases. *Plast Reconstr Surg*. 1999;104:97–101.
6. Nakatsuka T, Harii K, Asato H, et al. Analytic review of 2372 free flap transfers for head and neck reconstruction following cancer resection. *J Reconstr Microsurg*. 2003;19:363–368; discussion 369.
7. Smit JM, Zeebregts CJ, Acosta R, et al. Advancements in free flap monitoring in the last decade: a critical review. *Plast Reconstr Surg*. 2010;125:177–185.
8. Moubayed SP, Mourad M, Urken ML. What are the optimal monitoring techniques in head and neck microvascular reconstruction? *ORL J Otorhinolaryngol Relat Spec*. 2016;78:241–244.
9. Konijnenburg M, Stanzione S, Yan L, et al. A multi(bio)sensor acquisition system with integrated processor, power management, 8 x 8 LED drivers, and simultaneously synchronized ECG, BIO-Z, GSR, and two PPG readouts. *IEEE J Solid State Circuits*. 2016;51:2584–2595.
10. Lee S, Grundlehner B, van der Westen RG, et al. Nightingale V2: low-power compact-sized multi-sensor platform for wearable health monitoring. *Annu Int Conf IEEE Eng Med Biol Soc*. 2019;2019:1290–1293.
11. Abay TY, Kyriacou PA. Photoplethysmography for blood volumes and oxygenation changes during intermittent vascular occlusions. *J Clin Monit Comput*. 2018;32:447–455.
12. Yang Y, Soyemi O, Scott PJ, et al. Quantitative measurement of muscle oxygen saturation without influence from skin and fat using continuous-wave near infrared spectroscopy. *Opt Express*. 2007;15:13715–13730.
13. Comerota AJ, Throm RC, Kelly P, et al. Tissue (muscle) oxygen saturation (StO_2): a new measure of symptomatic lower-extremity arterial disease. *J Vasc Surg*. 2003;38:724–729.
14. Lai N, Zhou H, Saidel GM, et al. Modeling oxygenation in venous blood and skeletal muscle in response to exercise using near-infrared spectroscopy. *J Appl Physiol (1985)*. 2009;106:1858–1874.